

The Treatment of a Nondisplaced Radial Spiral Fracture in a Standardbred Horse

- A Case Report -

Dr. Sabine Wettengel

IVAS Congress Niedernhausen 2007

History:

- **DIAMOND ROAD**, a 20 year old standardbred gelding got kicked by a paddock companion.

IVAS Congress Niedernhausen 2007

Examination:

- Non weight bearing of right front leg

Examination:

- An open wound

Examination:

- Subluxations

Examination:

- Radiographs:
Nondisplaced spiral fracture

Owner: Weiffengel, Sabine
Pat: Diamand Road
Species:

Tierarztpraxis
Dr. Georg Veith

Geb: 01.01.1986
Breed: 1
Sex: O

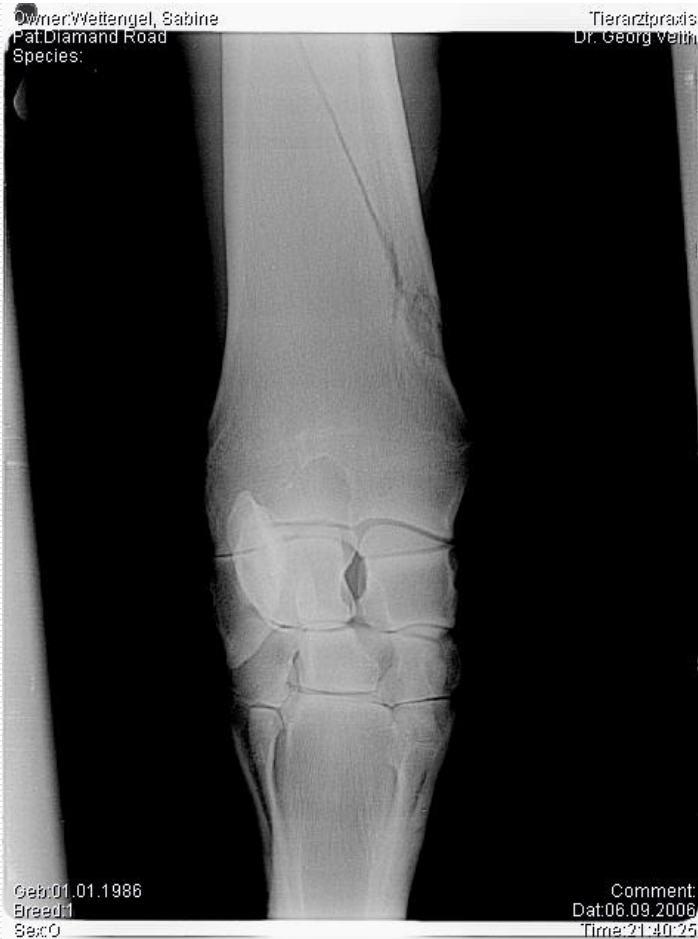Comment:
Dat: 06.09.2006
Time: 21:38:32

Owner: Weiffengel, Sabine
Pat: Diamand Road
Species:

Tierarztpraxis
Dr. Georg Veith

Geb: 01.01.1986
Breed: 1
Sex: O

Comment:
Dat: 06.09.2006
Time: 21:43:02



Examination:

- Non weight bearing of right front leg
- An open wound
- Subluxations
- Radiographs: Nondisplaced spiral fracture

Treatment:

- Bachflowers

Treatment:

- Aquapuncture with Traumeel

Treatment:

- Manipulation


Treatment:

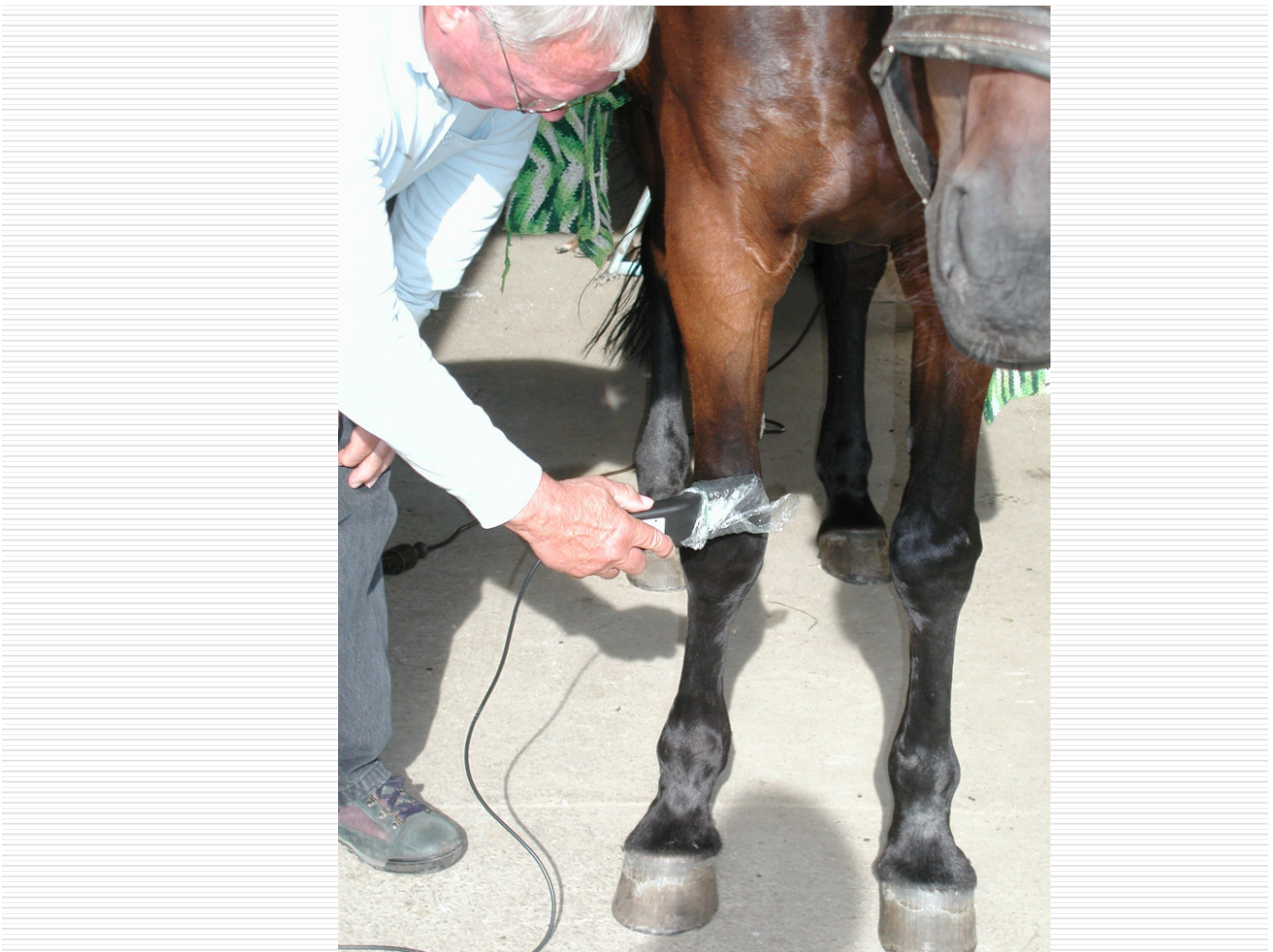- Antiinflammatory and Antibiotic Treatment

Treatment:

- Daily routine:
 - wound management
 - Hydrotherapy
 - laser therapy
 - Magnetic blanket plus leg wraps
 - Bandaging support
-

IVAS Congress Niedernhausen 2007



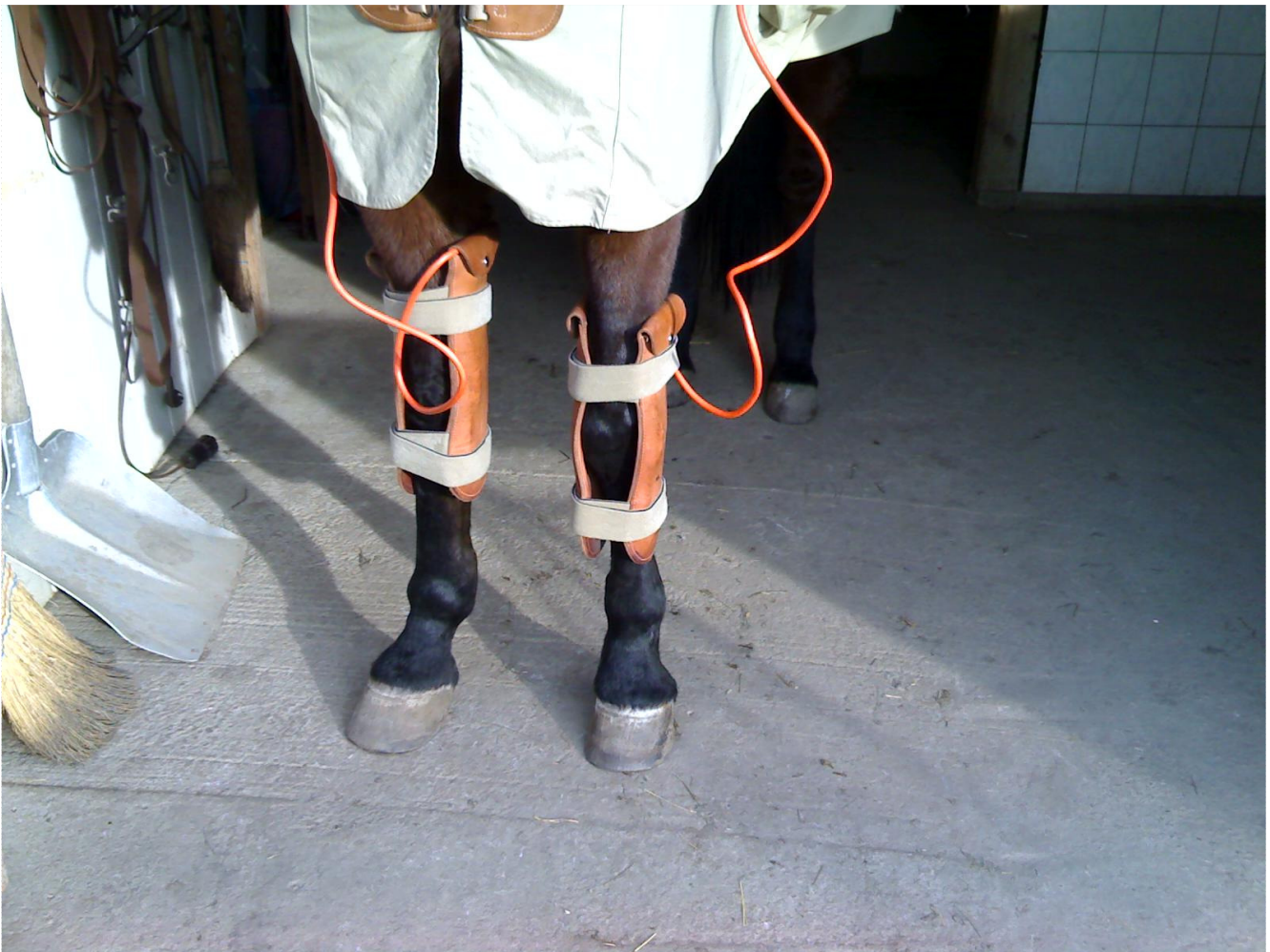

Treatment:

- Daily routine:
 - wound management
 - Hydrotherapy
 - laser therapy
 - Magnetic blanket plus leg wraps
 - Bandaging support
-

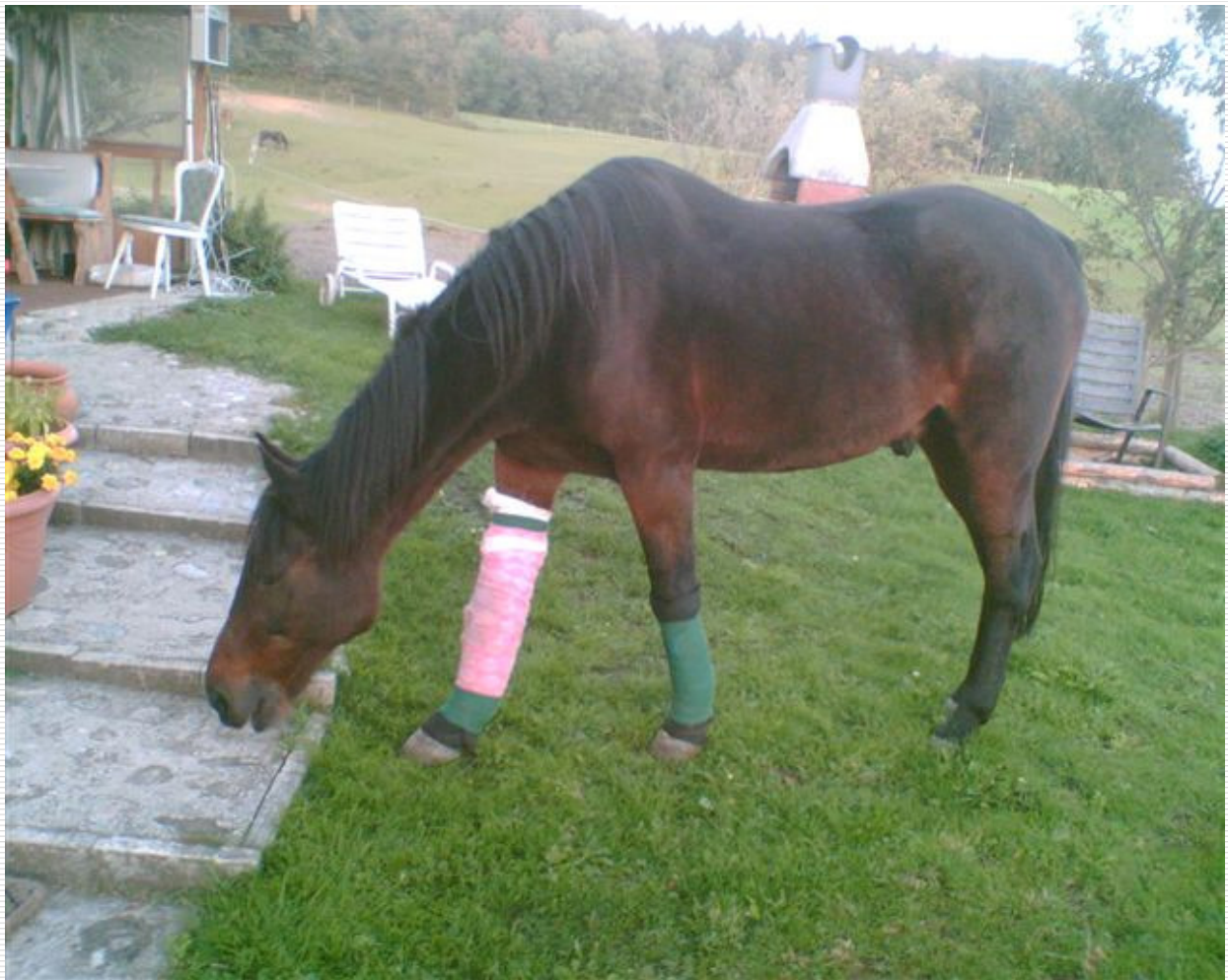IVAS Congress Niedernhausen 2007

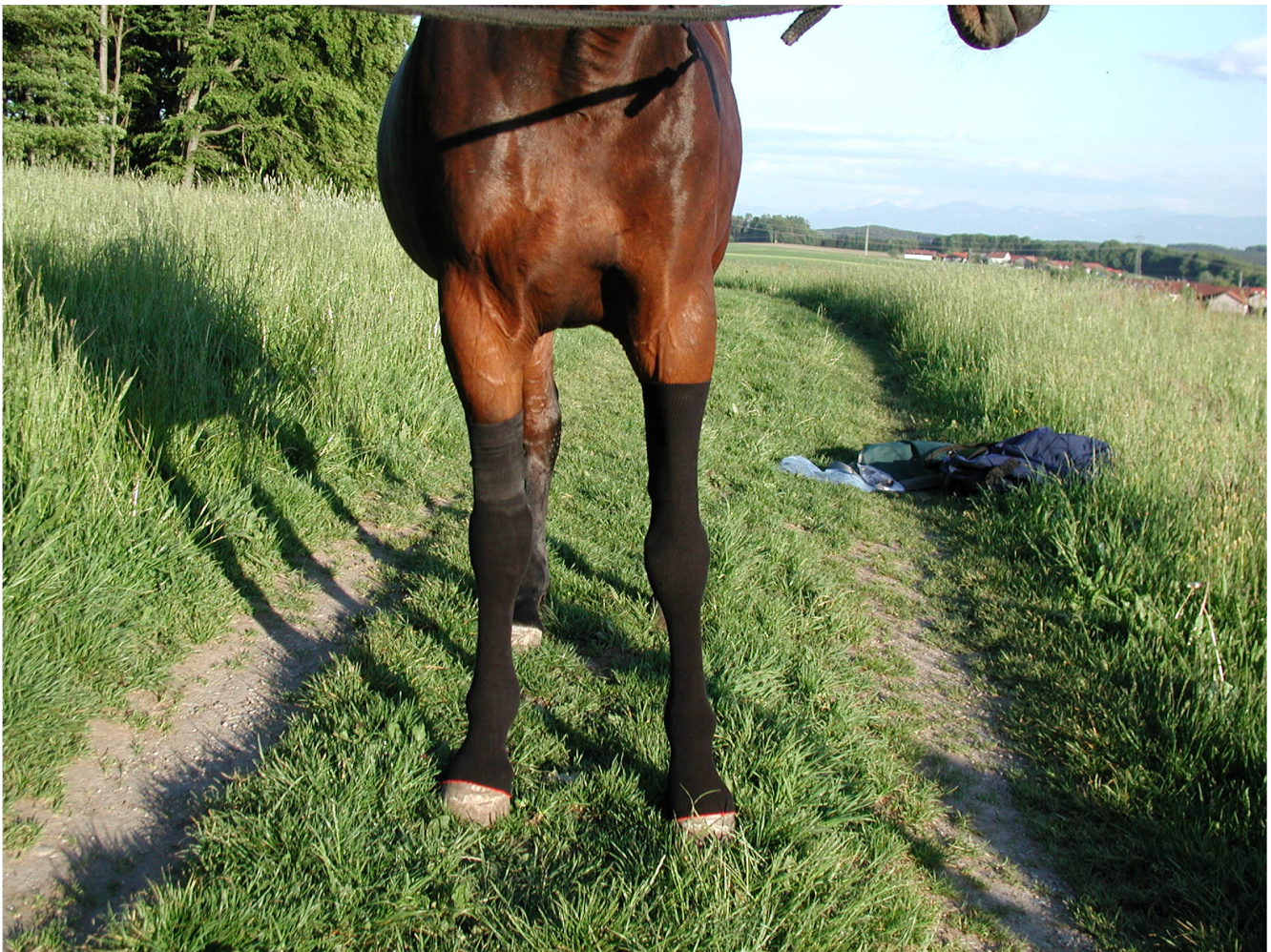



Treatment:

- Daily routine:
 - wound management
 - Hydrotherapy
 - laser therapy
 - Magnetic blanket plus leg wraps
 - Bandaging support
-





Treatment:

- Traumeel per os

Treatment:

➤ "Oxazen"

Treatment:

➤ "Mega Horse"

Treatment:

- Chinese Herbs "Central Mansion"

Treatment:

- Paddock (20x5m)

Treatment:

- Laser acupuncture

IVAS Congress Niedernhausen 2007

Treatment:

- Bachflowers
- Aquapuncture with Traumeel
- Manipulation
- Antiinflammatory and Antibiotic Treatment
- Daily routine:
 - wound management
 - Hydrotherapy
 - laser therapy
 - Magnetic blanket plus leg wraps
 - Bandaging support
- Traumeel per os
- "Oxazen"
- "Mega Horse"
- Chinese Herbs "Central Mansion"
- Paddock (20x5m)
- Laser acupuncture

IVAS Congress Niedernhausen 2007

Development:

- little improvement for three days => Radiographs

Development:

- at day 8 acute signs of laminitis plus severe blockages

Development:

- at day 17 acute blockages

Development:

- Control Radiographs after 4 weeks

Owner: Weitzel, Sabine
Pat: Diamond Road
Species:

Tierarztpraxis
Dr. Georg Veith

Geb: 01.01.1986
Breed: 1
Sex: 0

Comment:
Dat: 05.10.2006
Time: 16:36:26

Owner: Weitzel, Sabine
Pat: Diamond Road
Species:

Tierarztpraxis
Dr. Georg Veith

Geb: 01.01.1986
Breed: 1
Sex: 0

Comment:
Dat: 05.10.2006
Time: 16:38:27

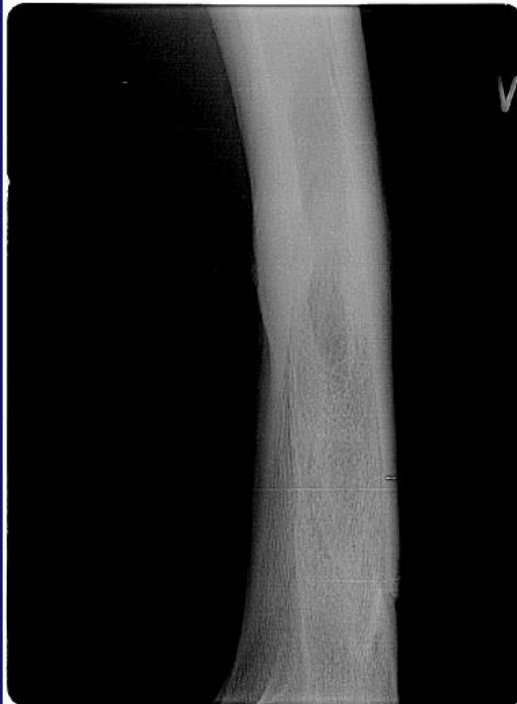Development:

- Control Radiographs after 10 weeks

IVAS Congress Niedernhausen 2007

Owner: Weitengel, Sabine
Pat: Diamond Road
Species:

Tierarztpraxis
Dr. Georg Veith



Geb: 01.01.1986
Breed: 1
Sex: 0

Comment:
Dat: 16.11.2006
Time: 11:50:52

Owner: Weitzengel, Sabine
Pat: Diamand Road
Species:

Tierarztpraxis
Dr. Georg Veith

VR

Geb: 01.01.1986
Breed: 1
Sex: 0

Comment:
Dat: 16.11.2006
Time: 11:49:01

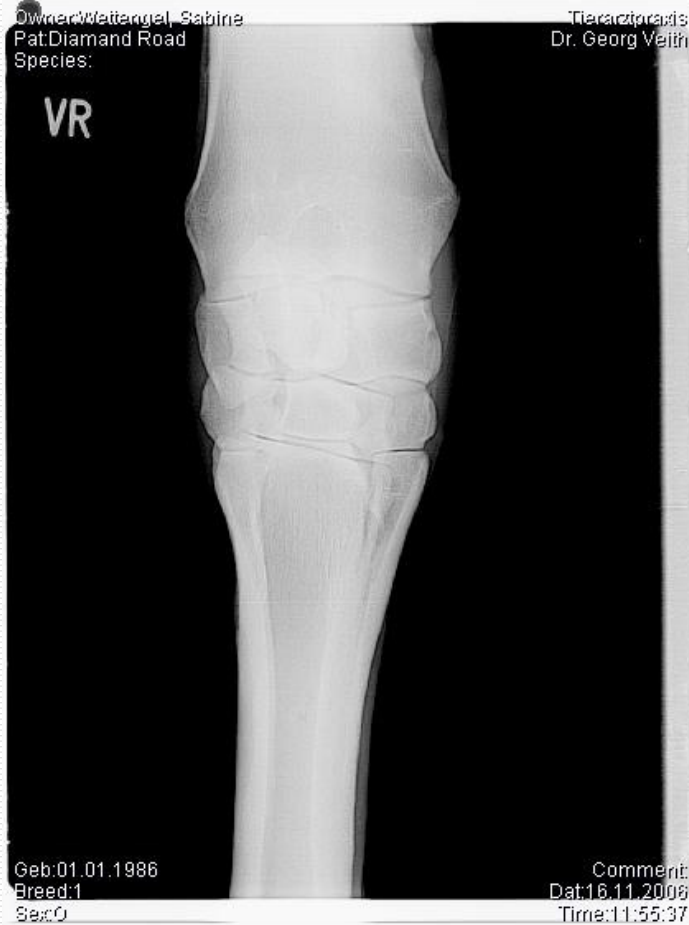Owner: Weitzengel, Sabine
Pat: Diamand Road
Species:

Tierarztpraxis
Dr. Georg Veith

VR

Geb: 01.01.1986
Breed: 1
Sex: 0

Comment:
Dat: 16.11.2006
Time: 11:58:58



Development:

- first steps trotting after 7 weeks

Development:

- At week 8 start of recovery program

Development:

- little improvement for three days => radiographs
- at day 8 acute signs of laminitis plus severe blockages
- at day 17 acute blockages
- control radiographs after 4 and 10 weeks
- first steps trotting after 7 weeks.
- At week 8 start of recovery program

Evaluation

Hard time

but worth a try !!!

